

## Bruises in infants and children: When to consider abuse. Part 2: accidental v non-accidental bruises

### Summary: bruising indicative of abuse

The Royal College of Paediatrics and Child Health (RCPCH) Child Protection Evidence systematic review on bruising, July 2017, found the following to be significant in identification of bruising indicative of abuse:

1. **Non-mobile infants** - bruising in children who are not independently mobile
2. **Site of bruising** - bruises away from bony prominences, or to face, abdomen, arms, buttocks, ears, neck, and hands
3. **Multiple bruises** in clusters or of uniform shape
4. **Imprints** - bruises that carry the imprint of an implement or ligature
5. **Petechiae** - bruises accompanied by petechiae in the absence of bleeding disorders

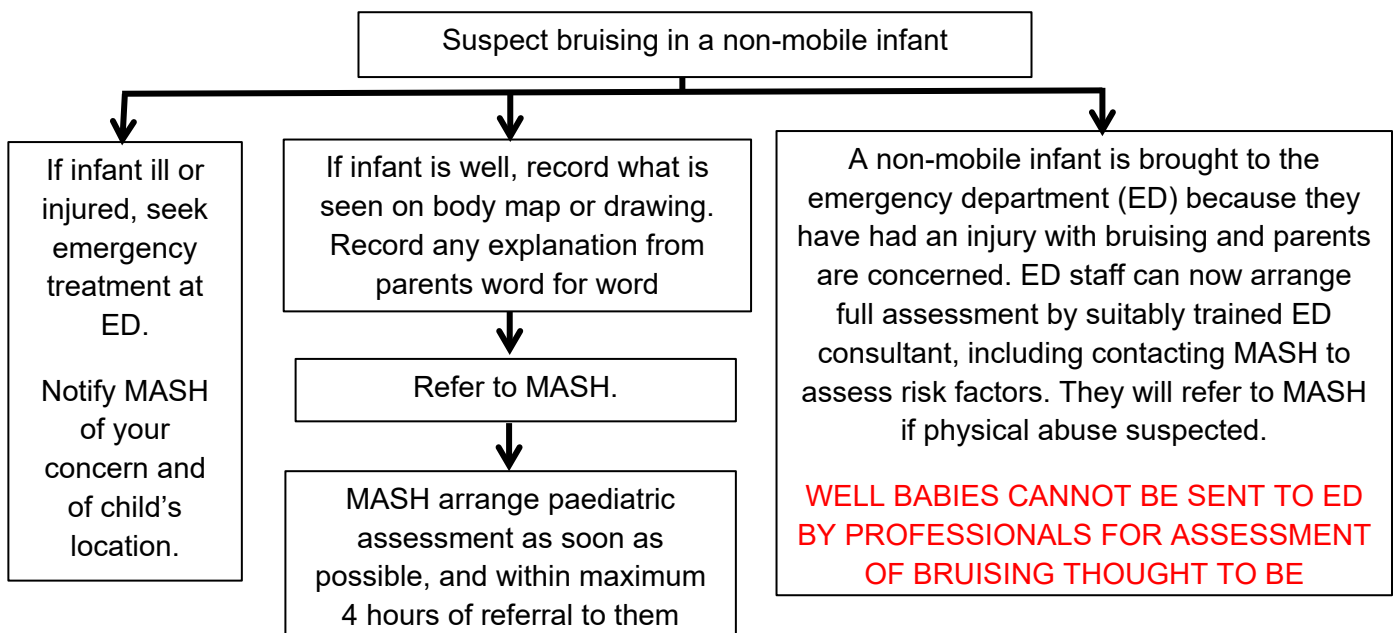
### Non-mobile infants

The number of accidental bruises increases as children get older and their mobility increases. Accidental bruises are rare in non-mobile babies (0-2.2%). Abuse should almost always be suspected if bruises are found in them.

Sheets et al found that in infants with confirmed abuse, the most frequent injury identified prior to this was a bruise. At least 19% of children found to have abusive brain injury had a previous bruise suspicious for abuse that hadn't been acted on and in 27.5% cases of physical abuse there was a history of escalating and repeated violence towards the infant (i.e. not a momentary loss of control)<sup>1</sup>.

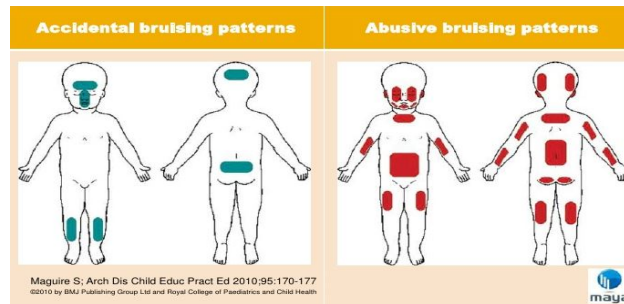
A recent local audit of well babies under 6 months having skeletal survey for suspected non-accidental bruising from 2013-2018, showed that 9% of babies had occult fractures.

The protocol for the management of actual or suspected bruising or other injury in infants who are not independently mobile can be found on <https://hipsprocedures.org.uk/>. A summary is in the flowchart below:



<sup>1</sup> Sheets LK et al. Sentinel Injuries in infants evaluated for child physical abuse. *Paediatrics*. 2013;131(4):701-7.

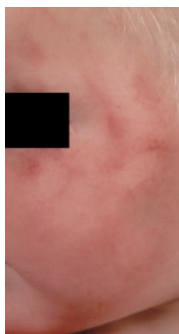**Site of bruising** - Consider abuse if bruises are away from bony prominences



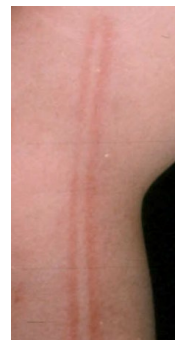**Multiple bruises** - Clusters of bruises are a common feature in abused children. These are often defensive injuries as the child tries to protect their head: on the upper arm, side of chest, outside of the thigh, or bruises on the trunk and adjacent limbs<sup>1</sup>.

Clusters of bruises are uncommon in accidental injury except for falls from a height >1m, stair falls, sports injuries and motor vehicle collisions<sup>2</sup>.

**Imprints** - Abusive bruises can carry the imprint of the implement used.



e.g. a slap mark



a cane

**Petechiae** - Petechial bruising in the absence of an underlying bleeding disorder can indicate an abusive injury. Nayak et al found that the presence of petechiae with bruising occurs more commonly in abuse than accidental injuries (positive predictive value of 80.0)<sup>3</sup>. Petechiae on or above the neck can occur as a result of suffocation or strangulation.

**Ageing bruises** - The Royal College of Paediatrics and Child Health (RCPCH) Child Protection Evidence systematic review on bruising, July 2017 found that it is **not** possible to age a bruise by examining it with the naked eye

- Different colours appear in the same bruise at the same time
- Not all colours appear in every bruise
- In general red, blue and purple were more commonly seen in bruises less than 48 hours old and yellow, brown and green were most often seen in bruises over 7 days old. However, the converse was true: red, blue and purple were identified in up to 30% of observations in bruises older than 7 days and yellow, brown or green were seen in up to 23% of bruises less than 48 hours old.
- Observers vary in how they interpret and describe colour.

1 The Royal College of Paediatrics and Child Health (RCPCH) Child Protection Evidence systematic review on bruising, July 2017 [https://www.rcpch.ac.uk/sites/default/files/2018-07/child\\_protection\\_evidence\\_-\\_bruising.pdf](https://www.rcpch.ac.uk/sites/default/files/2018-07/child_protection_evidence_-_bruising.pdf)

<sup>2</sup> Hibberd et al. Childhood bruising distribution observed from eight mechanisms of unintentional injury, *ADC* 2017;102: 1103-9

<sup>3</sup> Nayak K., Spencer N., Shenoy M., et al. How useful is the presence of petechiae in distinguishing non-accidental from accidental injury? *Child Abuse Negl* 2006; 30(5): 549-555.

**Bruising in children with disabilities** - Disabled children are 3-4 times more likely to be abused than non-disabled children. Accidental injury increases with mobility. Accidental bruising is unusual in non-mobile children, but can occur as a result of hoisting and transfers in wheelchair users. Accidental bruising commonly occurs on the feet, knees and thighs in physically disabled children. Bruises on the hands, arms and abdomen can be commoner in disabled than non-disabled children. Accidental bruises are rarely found on the ears, neck, chin, anterior chest and genitalia.

## Resources

The protocol for management of bruising in non-mobile infants can be found on <https://hipsprocedures.org.uk/qkyoz/children-in-specific-circumstances/bruising-in-infants-who-are-not-independently-mobile>

National Institute for Health & Care Excellence (2009) When to Suspect maltreatment in under 18s. <https://www.nice.org.uk/guidance/cg89>

National Institute for Health & Care Excellence (2017) Child abuse and neglect. Social care guideline 76: <https://www.nice.org.uk/guidance/ng76>

Royal College of Paediatrics and Child Health (RCPCH) (2013) Child Protection Companion. <http://pcouk.org/book.aspx?bookid=1674>